EXTRACORPOREAL RENAL SURGERY

Work Bench Surgery

J. M. GIL-VERNET, M.D.
A. CARALPS, M.D.
L. REVERT, M.D.
J. ANDREU, M.D.
P. CARRETERO, M.D.
J. FIGULS, M.D.

From the Urology Service, Hospital Clinico Provincial,
and University of Barcelona,
Barcelona, Spain

ABSTRACT — In cases in which renal repair through conventional in situ surgery is not possible, we have proceeded to remove the organ outside of the human body and placed it on a work bench where ex situ repair is aided by microsurgery, x-ray films, and image amplifiers. In most cases the damaged kidney has recovered its function and a grave problem has been solved. Extracorporeal surgery means a new tactical solution to extreme situations.

Advances made in renal transplantation such as the successful preservation of the ischemic kidney for several hours and improvement in the techniques of vascular anastomoses and reestablishment of continuity of the upper urinary tract, together with simultaneous developments in microsurgery, have given rise to bold surgery for severe damage to the kidney. The removal of the damaged kidney and its repair outside the human body, with subsequent reimplantation, is now a reality in those cases in which conventional surgery with reparation in situ is not technically possible. It is a transitory nephrectomy.

Our purpose was (1) to find a new surgical technique for extreme situations in which nephrectomy or permanent nephrostomy is not possible or desirable (such as in patients with a single kidney or when the other kidney is not normal); and (2) to make surgery possible in certain kidney diseases or diseases of the vessels of the kidney where surgery in situ would be impossible or dangerous. These are situations produced by peculiar anatomic conditions or by singular pathologic circumstances.

Indications for such a procedure include: repeated operated kidney, with cicatricial scarring of the pelvis or ureteropelvic junction and especially of the intrasinusoidal structures; dense fibrotic adhesions surrounding and involving the hilum and presenting serious vascular risks during dissection of the renal collecting system; ureterocalyceal anastomotic failures; certain recurrent staghorn calculi with urinary infection where conventional surgery cannot guarantee complete removal of calculi; severe tissue damage preventing plastic reconstructive operations that require the use of healthy tissues (ureter, pelvis, or intestine) and necessitate the removal of the kidney to another position in the pelvic cavity; failure of corrective operations for congenital malformations of the kidney with obstruction; intrasinusoidal renovascular pathologic conditions (stricture of small arterial branches, dyplasias, aneurysms, arteriovenous fistulas) which require the use of microsurgical techniques; such techniques are difficult to carry out in situ because of inadequacy of renal sinus capsule and also because of the risk of prolonged renal ischemia or

Presented at the XVII Congress of The International Society of Urology, Amsterdam, July, 1973.

operative hemorrhage; and vascular anomalies (polar arteries) in donor kidneys.

Rationale

Extracorporeal renal surgery is the offshoot of the enormous experience gained in kidney transplantation:

1. The transplanted kidney functions perfectly in a state of complete denervation.

2. Lymphatic drainage is restored through lymphatic-venous connections or through regeneration of the vessels. If not restored, it appears that lymphatic drainage is not essential for the correct functioning of the kidney.

3. With present methods of renal preservation (perfusion with Collins-3 solution and maintenance at 4° C.) the kidney is protected from the effects of ischemia during the time required for its repair without its function being altered and with immediate reestablishment of diuresis.

4. Our experience with the clinical results with isotransplants (1 case due to terminal uremia) and uni- or bilateral autotransplants (20 cases due to stricture of the renal artery, 2 cases due to extensive stricture of the lumbar ureter) show that secretory and excretory physiologic functions are completely normal in the transplanted kidney, mortality is not prohibitive (no mortality), and vascular complications (thrombosis or stenosis) not significant (no thrombosis or stenosis). Although extracorporeal renal surgery does not result in deleterious consequences to the kidney or the patient, it requires that the parenchyma be fairly thick and that the urologist be well trained in vascular surgery.

Surgical Techniques

The vascular configuration in the kidney as well as the iliac vessels must be previously known by means of aortography. After multiple retroperitoneal operations, the kidney may become closely adherent to the superficial layers and a different route of access such as a transperitoneal approach may be necessary. A lumbar approach may result in lacerations of the parenchyma and further reduce precariously an already lessened renal function.

Stages

First stage. Dissect the proximal trunk of the renal artery (renoaortic ostium) and the renal vein (the cava on the right side or its intersection with the aorta on the left side), and ligate the collateral vessels. This allows an eventual control of the hemorrhage, by means of Bulldog clamps, and ligature of the pedicle prior to the temporary nephrectomy. After this the kidney is freed by means of scissors.

The technique will differ if following ex situ repair the kidney is reimplanted in its place of origin, reanastomosed to its own vessels, as in cases with vascular indications, or if it is reimplanted in another area (ipsi- or contralateral iliac fossa) as in cases with urologic indications.

Second stage. In freeing the kidney, it is always preferable to include with the organ and surrounding tissues fragments from the superficial and deep-set parietal muscles rather than leave behind some renal parenchyma attached to the muscles. The kidney is removed along with the perirenal tissue or fibrous adhesions to which it may be attached.

Third stage. Immediately after removal the kidney is transferred to another surgical area where intra-arterial perfusion is carried out with Collins-3 solution. Once the perfusion is completed, the kidney is placed in a dish where it remains submerged in Collins-3 liquid to which magnesium sulfate has not been added. The temperature is kept at 4° C. and monitored by electronic telethermometer in the kidney and in the Collins' bath solution (Fig. 1).

To maintain a constant temperature of the renal bath, we first use a continuous pumping mechanism. However, simply adding and removing pieces of ice proved sufficient and adequate for maintaining the low temperature and viability of the organ (Fig. 2).

Preservation of renal function in the ischemic kidney involves other measures, such as the administration of hypertonic mannitol thirty minutes before opening the clamps and of furosemide at the moment of opening the clamps. Careful control of the blood volume and hydration of the patient is equally essential before, during, and after surgery. Supervision of the circulatory parameters, including the measuring of the central venous pressure are also essential.

Fourth stage. Ex situ repair is done at this stage. Motion of the kidney within the dish is prevented by supporting it with sponges. The organ is submerged, but the hilum remains on the surface, facing the surgeon. If surgery is expected to be lengthy, the kidney should be immersed completely 0.5 cm. from the surface during the procedure. Use of the operating binocular microscope allows more precise dissection and more

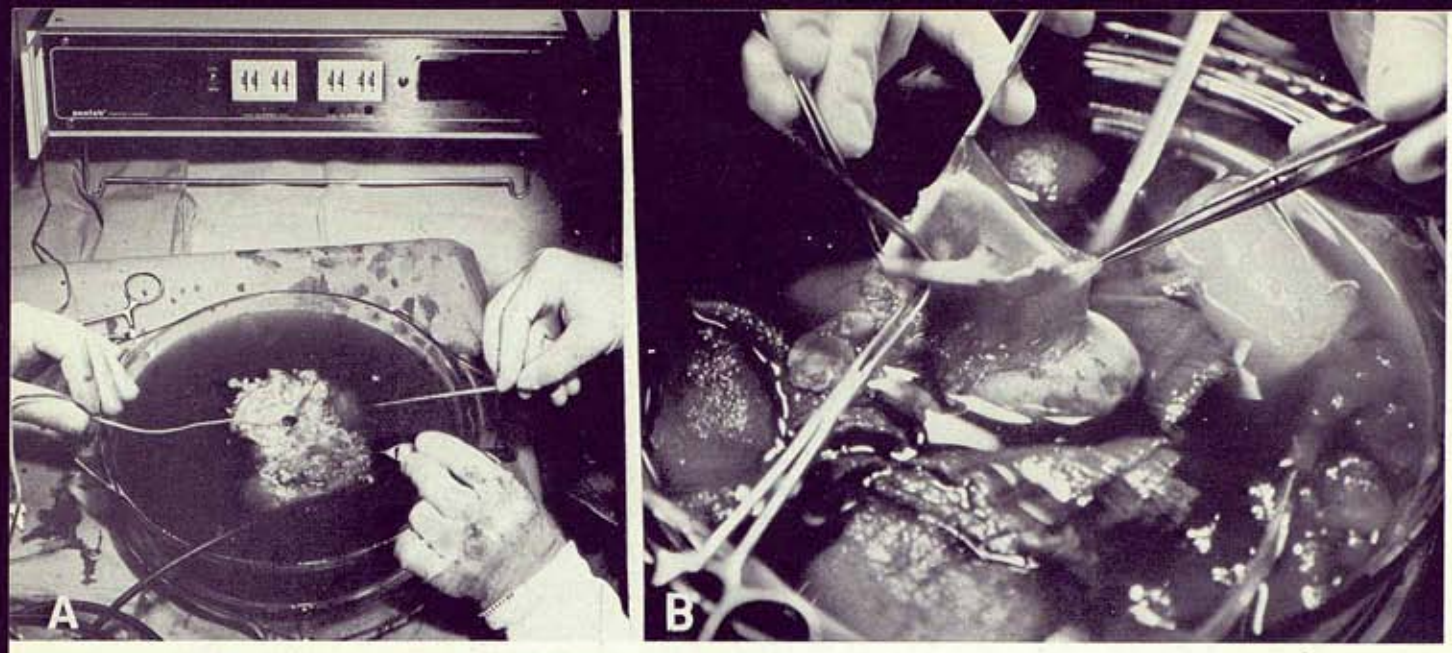

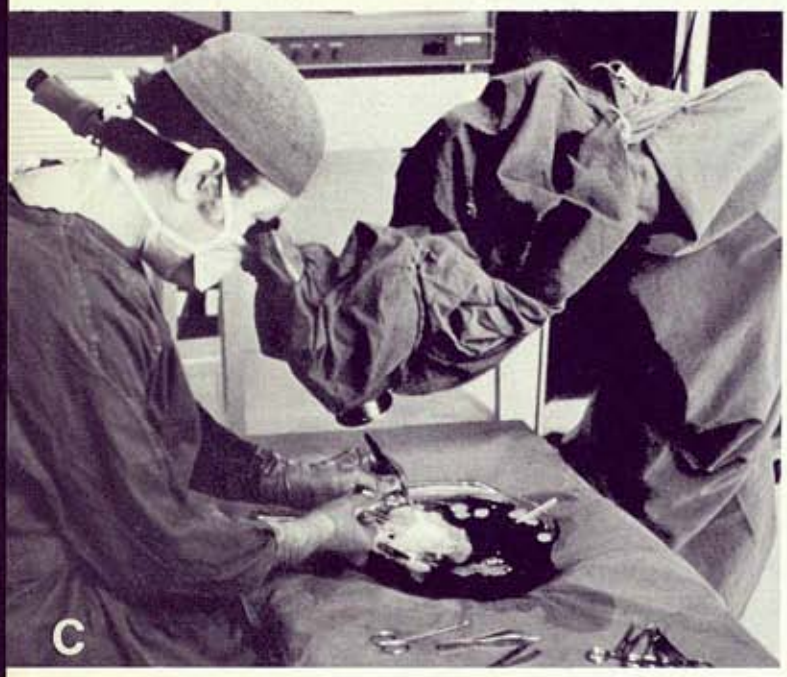

FIGURE 1. *(A) Pathologic kidney has been perfused and placed on dish with liquid kept at 4° C.; telethermometer allows constant control of temperature. (B) Extracorporeal operation: kidney is operated on in the dish and submerged in constant solution to keep it hypothermic. (C) Microsurgery is valuable because hilar structures are magnified.*

exact marking of the limits of the pathologic tissues, allows preservation of normal structures (branches of the renal artery), and allows surgery in the depth of the sinus (Fig. 3). In such conditions the identification of the different hilar structures, resections, anastomosis, and suture of the excretory tract or of the vessels is carried out easily (in a bloodless field) and with greater precision.

If the kidney also presents multiple calculi or staghorn calculus, it is placed directly on a radiographic chassis (Figs. 4 and 5). These films provide good and clear images, making it possible to detect the smallest calcification and to check that removal has been complete. The image intensifier is also useful for location of stones at various levels and their removal with minimum trauma (Fig. 6).

In renal transplantation it is not uncommon that both kidneys of a living donor have vascular anomalies (such as polar arteries); excision of a patch of the aorta is not necessary because once the kidney has been removed and perfused, the polar artery can be anastomosed to the trunk of the main artery, end to side, with the help of the operating microscope. Thus, regardless of the number of renal arteries, it is possible to use all kidneys for transplantation purposes.

Fifth stage. After completion of the ex situ operation, if the indication was for a vascular problem, the kidney may be reimplanted in its place of origin by reanastomosis of its vessels and renal pelvis. If stricture of the trunk is also present, it is preferable to transfer the kidney to another vascular area, except with the left kidney where the splenic artery can be used for a

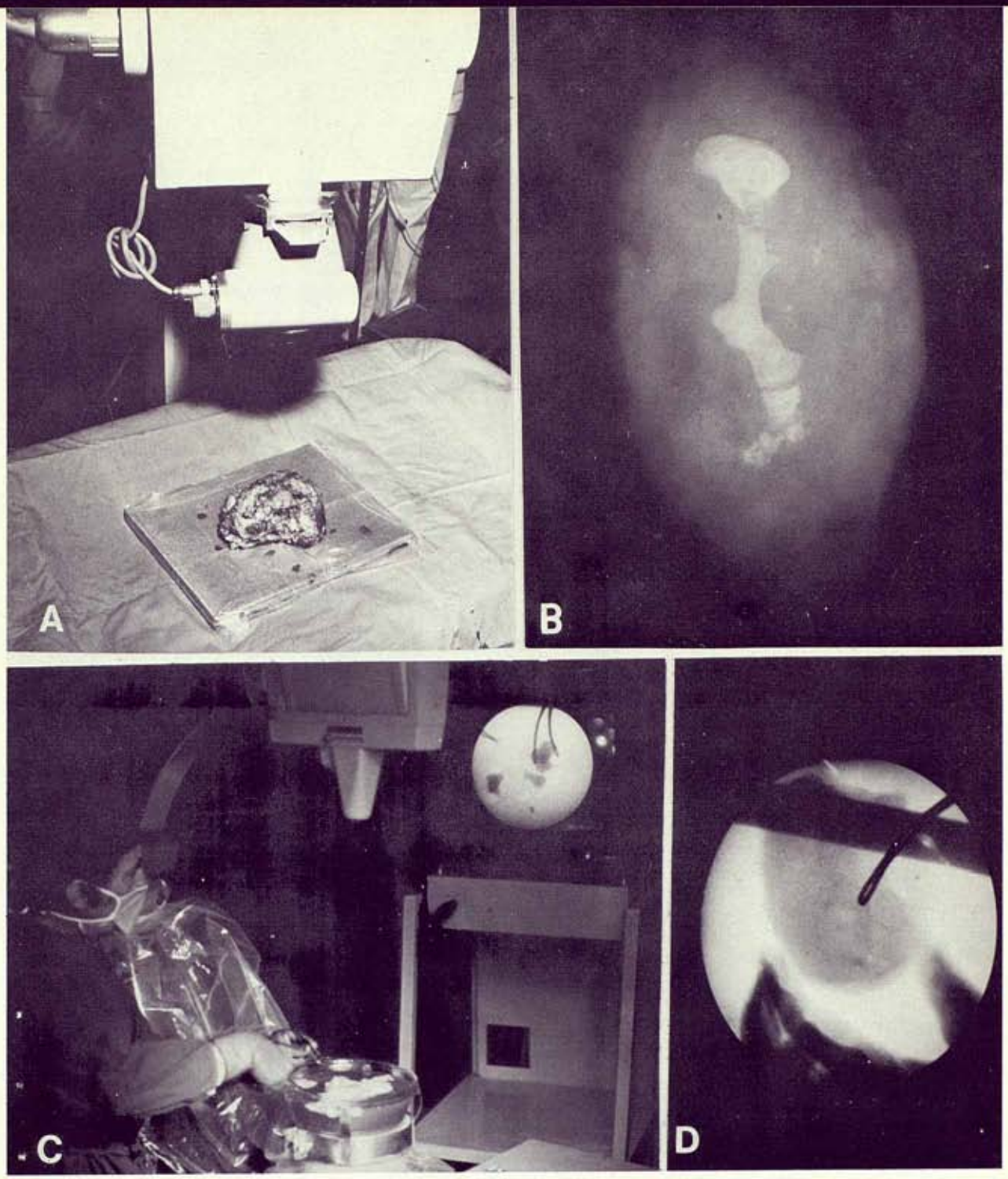

FIGURE 2. *(A) Kidney is brought to radiology department; (B) contact radiography: stone and calcifications are detailed; (C) image amplifier helps to locate and extract calculus with minimum trauma (dish containing kidney is radiotransparent); (D) television image: Randall's forceps is easily directed toward bottom of calyx to remove small stone.*

splenorenal anastomosis. If the indication was for a urologic problem, the kidney is transplanted to the iliac fossa where healthy iliac ureter can be used to reestablish urinary continuity. If reimplanted in the lumbar fossa, a pyelopyelic anastomosis would be necessary.

In extracorporeal surgery the ex situ stage is not difficult because it is carried out under conditions particularly favorable to the surgeon: lighting is perfect, structures are magnified, the organ is in his hands, ample time is available, and he is comfortably situated and separated from any tension-producing influence.

It is bloodless and atraumatic surgery. During surgery of the ex situ organ, the patient is under light anesthesia.

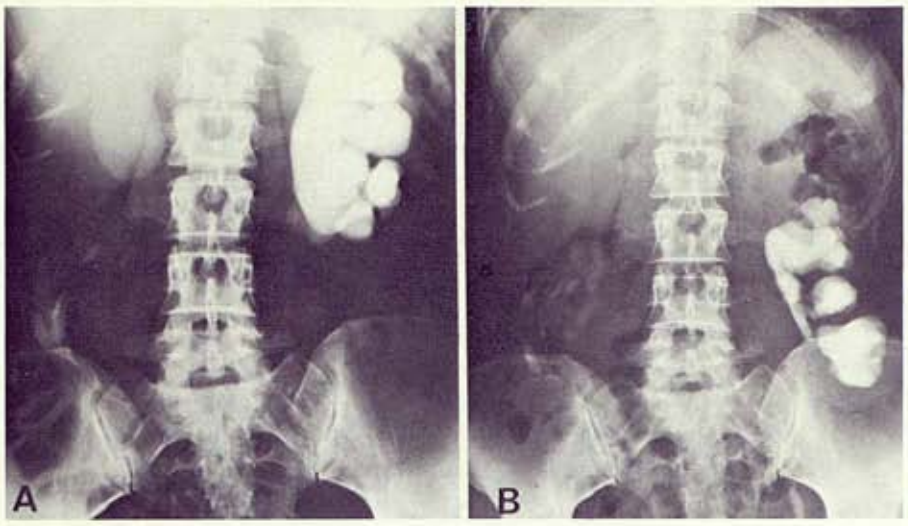

FIGURE 3. *Case 4. (A) Anomalous right kidney (lumboiliac ectopy); left kidney with large hydronephrosis complicated by extensive stricture of ureter caused by previous surgery. (B) Postoperative intravenous pyelogram: local condition of tissues made operation in situ impossible. Resection and intrasinusoidal pyeloplasty ex situ under microscope. Reimplanted kidney in lumboiliac area in inverted position.*

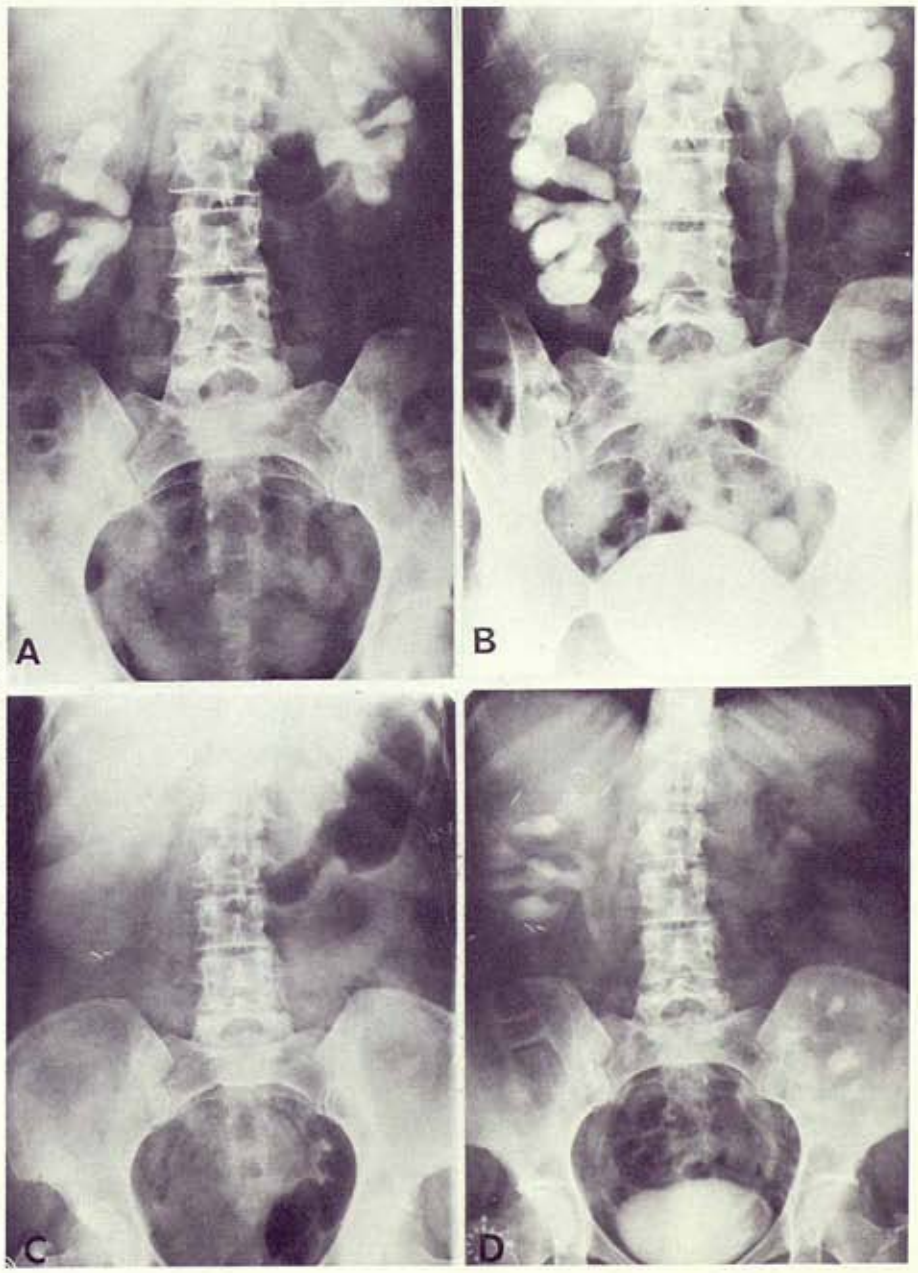

FIGURE 4. *Case 7. (A) Roentgenogram showing bilateral staghorn calculus; patient had two operations on left kidney. (B) Intravenous pyelogram showing extensive stricture of ureteropelvic junction on left side. (C) Postoperative roentgenogram revealing complete removal of stones on both sides. (D) Intravenous pyelogram, postextracorporeal surgery, showing left kidney in iliac fossa.*

Surgical Indications

Urologic

Urologic indications include: (1) strictures extending over the ureteropelvic junction and the pelvis, usually a sequela of surgery for lithiasis, when a correct technique is not followed; (2) recurrent staghorn calculi; (3) failures in plastic surgery for hydronephrosis, strictures following ureteral reimplantations and ureterocalyceal anastomoses where the restoration of the excretory tract according to conventional procedures is not possible; (4) congenital renal malposition or malrotation where it is possible to rectify the anomaly surgically and provide improved urinary drainage; (5) structural anomalies of the renal hilum that make normal conventional operations dangerous; and (6) multiple tumors in a single kidney in which selective antineoplastic chemotherapy may be used.

Vascular

The following are vascular indications: (1) vascular anomalies (26 per cent of cases) in donor kidneys in the form of polar arteries which cannot be ligated (partial nephrectomy is dangerous in

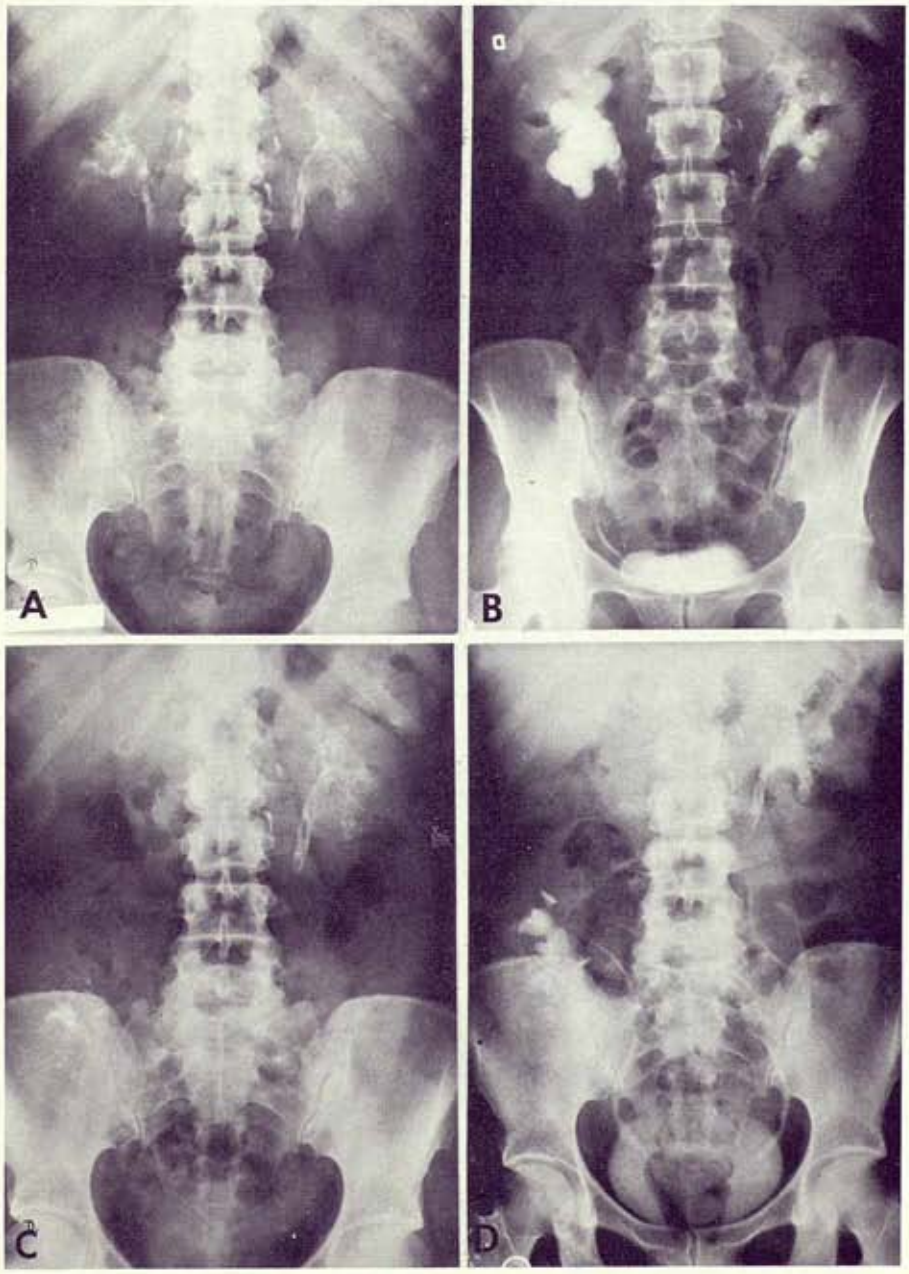

FIGURE 5. *Case 12. (A) Roentgenogram showing Thorotrast residue following bilateral pyelography. (B) Intravenous pyelogram: hydronephrosis from extensive fibrous stricture of ureteropelvic junction due to deposits of Thorotrast at adventitial layer. (C) Postoperative radiography: ex situ resection of lower portion of renal pelvis and lumbar ureter (right side) and partial removal of deposits of Thorotrast in the calyceal system using operating binocular microscope. (D) Postoperative intravenous pyelogram: transplanted kidney to iliac fossa.*

these cases); and (2) intrarenal aneurysms and arteriovenous communication and strictures of branches of the renal artery, especially when associated with stricture of the trunk. There is a single essential condition: that the kidney maintain sufficient function.

The indications for extracorporeal surgery are, for the moment, not very frequent but should not be ignored, particularly in the single kidney.

Results and statistics

Of a total of 12 cases of surgery, there were 10 successful results and 2 failures, with no mortality.

Case Abstracts

*Case 1**

This fifty-year-old man had congenital hydronephrosis on both sides. Conventional pyeloureteroplasty on the right side resulted in failure. There was no possibility for a new intervention in situ. Extracorporeal surgery in May, 1972, gave a good result.

Case 2

This eleven-year-old boy with permanent nephrostomy in a solitary kidney had a previous history of renoureteral trauma, severe pyelonephritis, and renal insufficiency. The purpose of the operation was to eliminate the permanent nephrostomy. Results of extracorporeal surgery in March, 1973, were considered to be unsatisfactory. In this case the mistake was failure to recognize that the injuries were nonreversible. This patient is awaiting allotransplantation.

Case 4

Previous surgery on the left kidney had been performed in this forty-nine-year-old woman. There was advanced hydronephrosis with hypoplasia of the lumbar ureter and of the ureteropelvic junction, and iliac ectopy of the contralateral kidney. A good result was obtained following extracorporeal surgery in May, 1973.

Case 7

This patient, a fifty-year-old woman, had bilateral staghorn calculi. The left kidney had multiple surgery followed by extensive stricture of the left ureteropelvic junction and lumbar ureter, and recurrence of the stone. There was impaired function of the right kidney. Extracorporeal surgery on the left kidney in June, 1973, gave a good result. Later, staghorn calculi of the right kidney were removed by conventional surgery (intrasinusoidal approach).

Case 8

A fifty-five-year-old man had bilateral staghorn calculi with multiple operations. In the left kidney there was extensive stricture of the ureteropelvic junction, a thinned parenchyma due to previous bivalve nephrotomy, and pyelonephritis. Extracorporeal surgery in June, 1973, was followed by total necrosis of the organ and required nephrectomy. The patient is living, with sufficient function of the remaining kidney. Two hypotheses that explain the cause of failure are: (1) malfunction of the temperature-regulating mechanism of the conservation liquid which was maintained under 0° during four and one half hours of the ex situ operation, and (2) by a deficient perfusion attributable to the effects of the previous bivalve nephrotomy.

Case 9

This woman, aged forty-five years, had a left renal staghorn calculus, repeated surgical procedures, intrasinusoidal in position, with scarred retraction of the pelvis, and hydronephrosis of the other kidney. A good result followed extracorporeal surgery in January, 1974.

Case 12

This forty-seven-year-old woman had a history of retrograde pyelography on both sides with Thorotrast (a contrast medium). This resulted in right hydronephrosis with fibrous stricture of the pelvis. Contralateral kidney was also affected, although without any morphologic alterations. Extracorporeal surgery performed in June, 1974, gave a good result.

Other cases

There were 5 cases (Cases 3, 5, 6, 10 and 11) of polar arteries in kidneys from live donors in which both organs revealed vascular anomalies. A successful surgical result was obtained in all.

Comment

Statistical results are satisfactory considering that these were very difficult cases, with repeated

*Case presented to the VI International Urology Course, July, 1972, Barcelona, Spain.

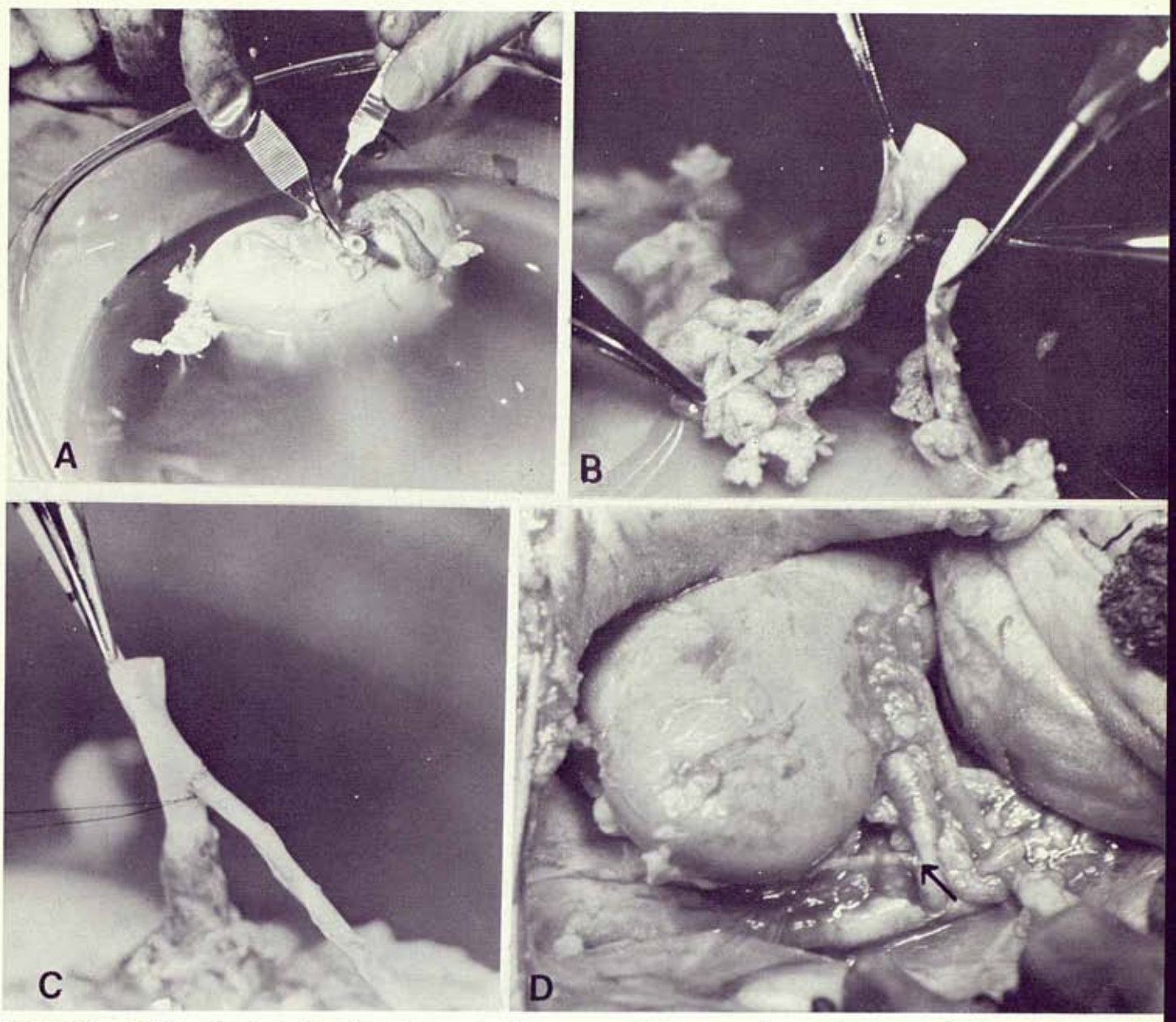

FIGURE 6. *(A) Vascular indication for extracorporeal surgery; renal homotransplant; polar artery of 1.5-mm. caliber. (B) Anastomosis end to side of polar artery to main arterial trunk. (C) Anastomosis is completed. (D) Homotransplant in iliac fossa; anastomosis of artery end to side with common iliac; arrow shows polar artery anastomosed to renal artery.*

surgical interventions, in which repair by conventional techniques was not possible and in which extracorporeal surgery was the only and maybe the last recourse.

The operation is justified since it avoids nephrectomy when the other kidney is not normal, avoids nephrostomy in a single kidney, and makes possible surgery which would be impracticable in situ.

The idea that nephrectomy is preferable if the other kidney is normal and, in the case of a single kidney, nephrostomy now ceases to be true.

Urology enters the stage of extracorporeal surgery with the successful repair of an organ outside the human body, and this opens to urology and surgery in other areas a new field of hopeful possibilities.

Cátedra de Urologia
Facultad de Medicina
Universidad de Barcelona
Casanova, 143
Barcelona 11, Spain
(DR. GIL-VERNET)